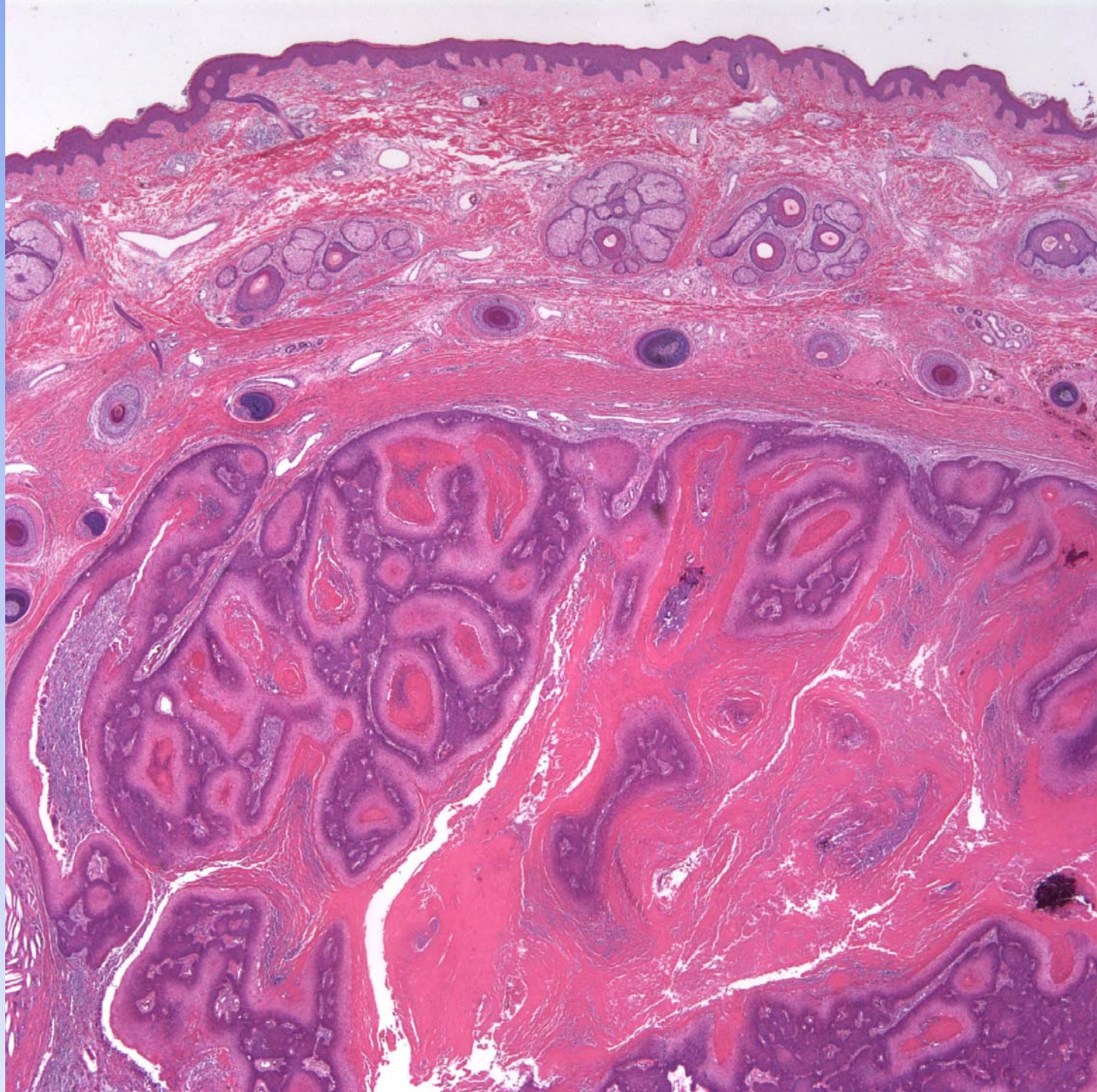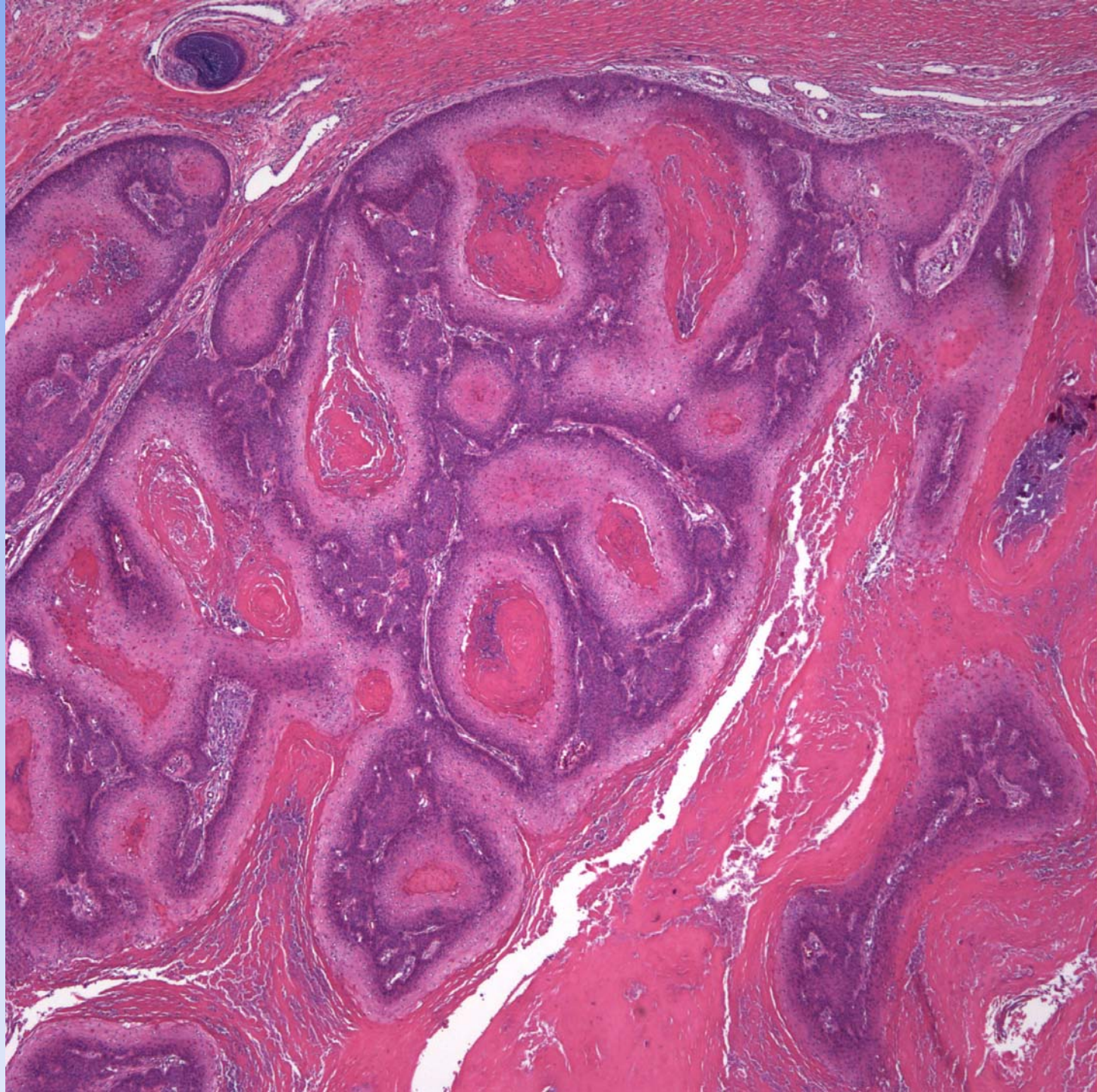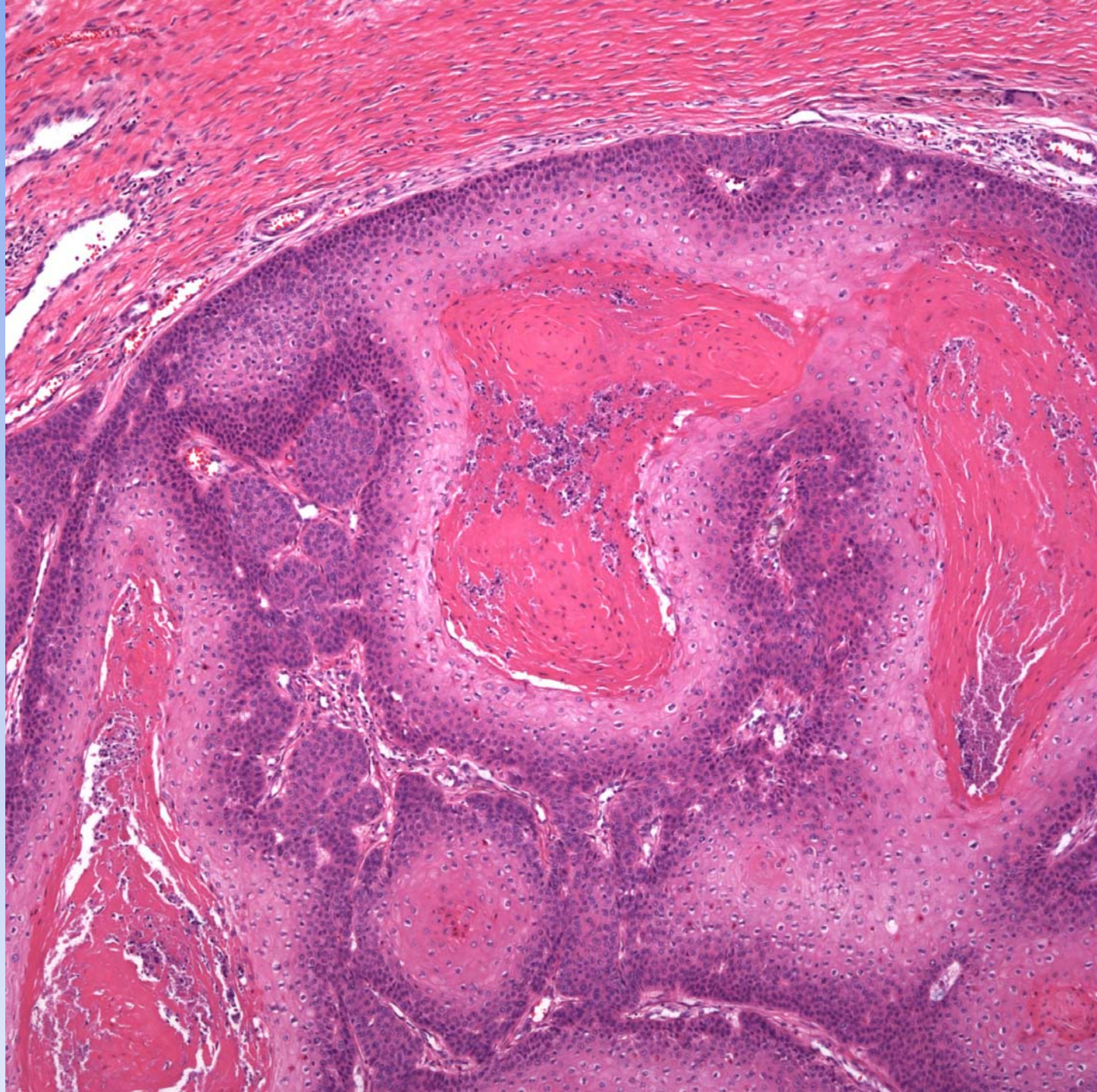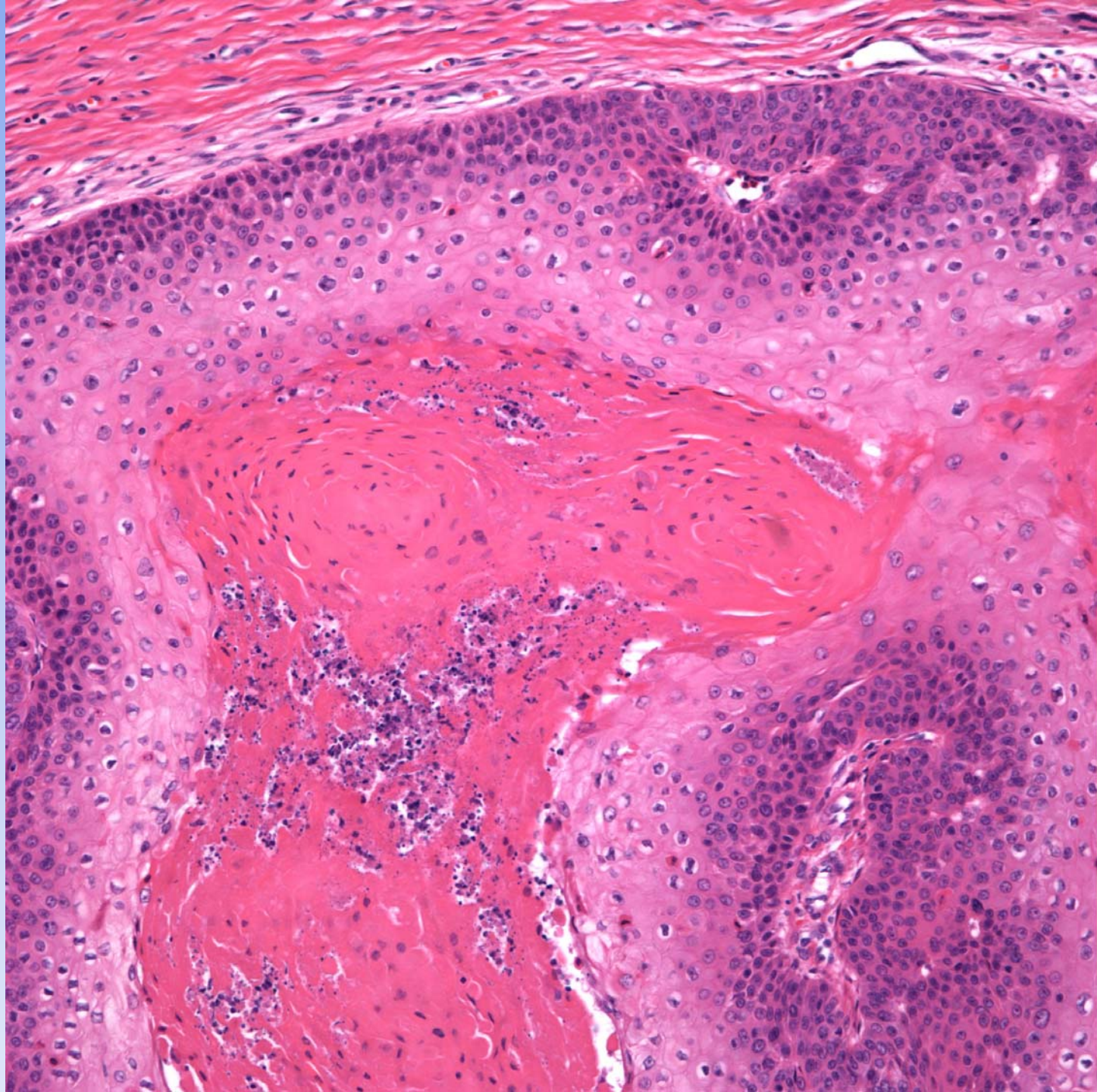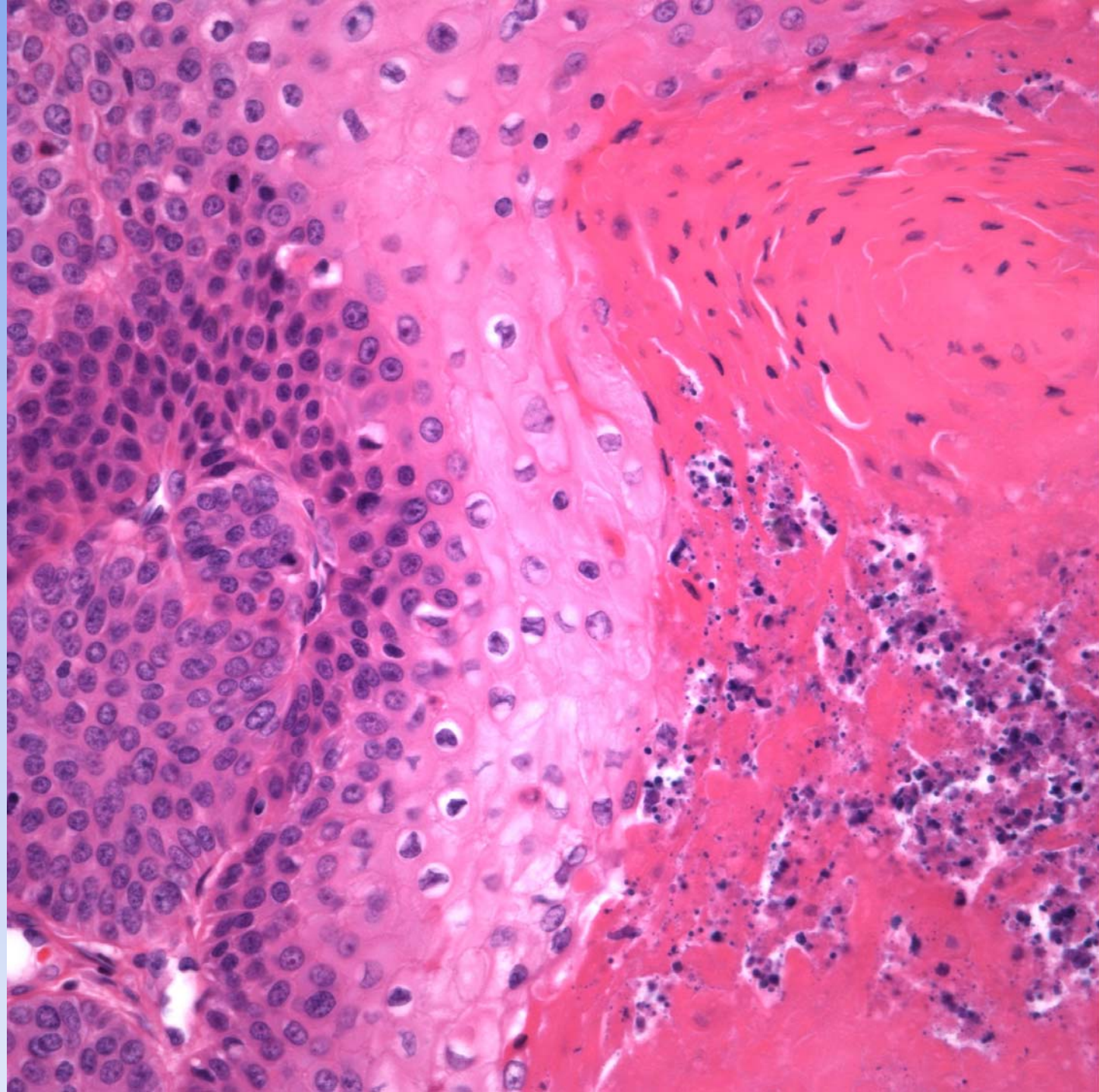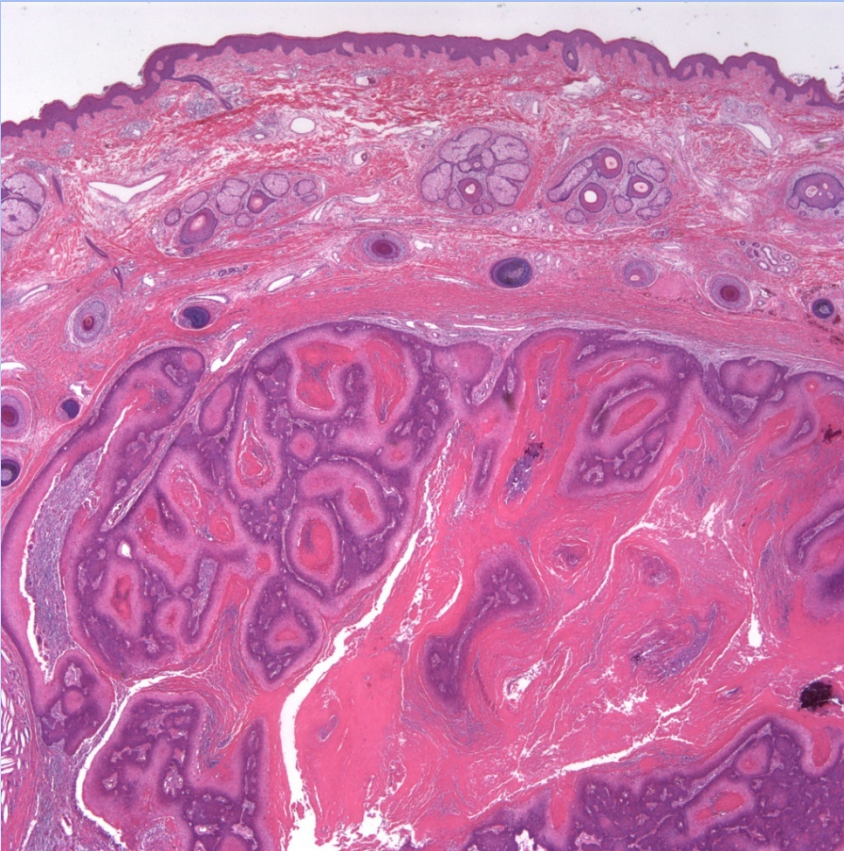


Proliferating Pilar Tumor

Pearls



- Circumscribed epithelial tumor with extensive pilar differentiation
- May have extensive necrosis with squamous debris
- Individually pleomorphic cells not uncommon
- Must view at low power and note rounded basal layer